

Aurolab Aqueous Drainage Implant With and Without Scleral Patch Graft in Refractory Adult and Pediatric Glaucomas: A Comparative Study



GEORGE VARGHESE PUTHURAN, PAUL PALMBERG, HIRUNI KAUSHALYA WIJESINGHE, KUMAR SAURABH SRIVASTAV, SUBBIAH RAMASAMY KRISHNADAS, AND ALAN LEE ROBIN

- **PURPOSE:** To compare the 2-year outcomes of eyes that received the Aurolab aqueous drainage implant (AADI) with and without a scleral patch graft.
- **DESIGN:** Retrospective comparative interventional case series.
- **METHODS:** Eyes with AADI and a minimum of a 2-year follow-up were included. Eyes that underwent implantation before January 2016 had surgery with a scleral patch graft covering the distal end of the tube, whereas those that were implanted after this period underwent surgery using a needle-generated scleral tunnel without the patch graft. The cumulative failure of the AADI was defined as intraocular pressure (IOP) > 18 mm Hg or not reduced by 30% below baseline on 2 consecutive follow-up visits after 3 months.
- **RESULTS:** We included 215 adult eyes (n = 147 with patch graft, n = 68 without patch graft) and 111 pediatric eyes (n = 73 with patch graft, n = 38 without a patch graft). The mean IOP in eyes without the patch graft was higher at 1 month in adult eyes (before, 27.5 ± 14.1 vs after, 22.3 ± 11.1; P = .01) but not in pediatric eyes (14.3 ± before, 5.8 vs after, 17.8 ± 11.0; P = .39); there were no differences in IOP, vision, number of antiglaucoma medications, and complications between groups at all other time points. None of the eyes without the patch graft experienced tube exposure. Cumulative success rates at 2 years in adults (66.2% vs 63.9%, respectively; P = .85) were similar to those in children (77.2% vs 71.9%, respectively; P = .83) with both techniques.
- **CONCLUSIONS:** AADI placed without a scleral patch graft is as safe and effective as AADI placed with a patch graft in pediatric and adult refractory glaucomas. (Am J Ophthalmol 2020;216:226–236. © 2020 Elsevier Inc. All rights reserved.)

GLAUCOMA DRAINAGE IMPLANTS HAVE GAINED popularity over the past decade for the management of refractory glaucoma, both in adults and in children.¹ Both valved and nonvalved implants are popular, and randomized controlled trials comparing these devices have shown good efficacy over a 5-year period with a slightly better control of intraocular pressure (IOP) with the Baerveldt implant (Johnson & Johnson Vision, New Brunswick, New Jersey); however, that implant also had a higher risk of hypotony than the Ahmed valve (New World Medical, Rancho Cucamonga, California).² The Aurolab aqueous drainage implant (AADI) (Aurolab, Madurai, India), a low-cost nonvalved variant, is a relatively recent addition to the armamentarium of drainage implants. It has been shown to be efficacious and safe over a 4-year period in both adult and pediatric eyes with refractory glaucoma.^{3–5}

A critical surgical step while placing any implant is to cover the distal 4 mm of the tube by using a donor scleral patch graft. This minimizes the risk of tube exposure, thereby reducing the chances of endophthalmitis. Despite this method, tube exposure has been reported in approximately 10% of cases regardless of the type of implant being used.^{6,7} Although procuring a scleral patch graft is desirable, it requires access to an eye bank. The lack of eye bank facilities throughout much of the developing world makes access to a scleral patch graft difficult, thereby reducing the use of drainage implants for deserving patients. To overcome this barrier, surgeons have tried different options to complete surgery without the scleral patch graft, including implanting the tube through a partial-thickness scleral groove initiated at various distances from the limbus using different instruments,^{8–12} using double-scleral tunnels in tandem,¹³ and using scleral flaps with Tenon's advancement and Tenon's reduplication.¹⁴ Alternatives to the sclera have also described the use of fascia lata and corneal tissue for covering the tube.^{15,16} Some of these materials have yielded excellent outcomes in the short term, and a study comparing end results with and without the patch graft showed equivalent outcomes at 1 year follow-up.¹²

Although the AADI has shown encouraging results in terms of IOP control and low incidence of vision-threatening adverse events, its efficacy without the use of

AJO.com

Supplemental Material available at AJO.com.

Accepted for publication Mar 17, 2020.

From the Glaucoma Services (G.V.P., S.R.K.), Aravind Eye Hospital, Madurai, India; Bascom Palmer Eye Institute (P.P.), University of Miami School of Medicine, Miami, Florida, USA; and the University of Michigan (A.L.R.), Lansing, Michigan, USA.

Inquiries to George Varghese Puthuran, Glaucoma Services, Aravind Eye Hospital and Institute of Ophthalmology, Madurai, Tamil Nadu 625020, India; e-mails: georgeputhuran@gmail.com; george@aravind.org

a scleral patch graft has not been studied until recently. The present study retrospectively compared 2-year outcomes of pediatric and adult eyes with refractory glaucoma that underwent the AADI implantation with and without a donor scleral patch graft.

SUBJECTS AND METHODS

THIS WAS A RETROSPECTIVE STUDY APPROVED BY THE Aravind Eye Hospital, Madurai, ethics committee (RET201300234) and followed all the tenets of the Declaration of Helsinki. Informed consent was obtained from all adults and parents of all children before surgical intervention. Records of all patients who underwent AADI implantation between January 2013 and May 2017 were identified and drawn from a computerized database and cross-checked with the operating room register. Case files of all these patients were screened, and data of those with a minimum follow-up of 2 years were included in the analysis.

After identifying eligible patients, their demographics such as age, sex, and residence were noted from the case files, followed by preoperative glaucoma parameters such as primary versus secondary glaucoma, underlying cause in secondary glaucomas, baseline IOP at the listing of surgery, number of antiglaucoma medications, baseline best corrected visual acuity (BCVA), surgical history, visual fields assessment in the adult patients, and the date of AADI surgery. The surgical techniques used for tube placement, that is, scleral patch graft versus no patch graft, were transcribed from the operation notes. The IOP, number of antiglaucoma medications, the BCVA, complications, and resurgery if any were recorded on day 1 and then at months 1, 3, 6, 9, 12, 18, and 24.

- **SURGICAL TECHNIQUE:** Eyes underwent AADI implantation in the superotemporal quadrant, using the scleral patch graft between January 2013 and December 2015, whereas those after this period underwent superotemporal AADI implantation using a needle-generated scleral tunnel without the patch graft in both the adult and the pediatric groups. All procedures were performed by 2 surgeons (G.V.P. and S.R.K.). A 350-mm² AADI was placed in both adult and pediatric eyes using the scleral patch graft in one of the groups as has been described previously.³ In the AADI implantation groups without the patch graft, the steps until fixation of the explant and watertight tube ligation were the same.

The tube was draped over the cornea, a mark was placed on the tube 2 mm anterior to the limbus, with the help of a Castroviejo straight caliper and a sterile marking pen, and the tube was trimmed bevel up at the mark. A scleral groove was fashioned 2 mm medial to the original position of the tube and 4 mm posterior to the limbus, and then the 23-gauge scleral track was initiated. Castroviejo straight

caliper and a marking pen were used to accurately mark the position of the scleral groove beforehand. A bent 23-gauge needle with bevel facing up was introduced at the initiation point of the scleral groove to create a partial thickness scleral tunnel track. The needle was aimed to remain at 50% scleral depth, shown by its visibility throughout. After the needle was initiated at the desired depth, it was progressively advanced forward. At three-fourths of the way to the corneal edge, the needle path begins to turn gradually to become parallel to and just above the iris plane for entry into the anterior chamber. During this maneuver, counter-traction is maintained by using a McPherson corneal forceps (1 × 2 teeth), grasping the dissected edge of the conjunctiva at the limbus, and the globe is rotated from a slight downward gaze to straight ahead, facilitating the surgeon's ability to judge when it is parallel to the iris plane at entry ([Supplemental Video 1](#)). The tube of the AADI in the bevel-up position was then threaded through this tunnel using a tube inserter (Model-1; New World Medical) forceps until it entered the anterior chamber, confirmed by the visibility of 2 mm of the tube inside the anterior chamber. This was followed by meticulous conjunctival closure using 8-0 polyglactin sutures (Aurolab), making sure that the Tenon's fascia was included in the closure and was covering the entire length of the tube.

Postoperative prescriptions included topical antibiotics used 4 times daily for 4 weeks, topical steroid drops for 12 weeks in a tapering dose, and topical cycloplegic eye drops once at night for 8 weeks. Antiglaucoma medications were continued depending on postoperative IOP levels until the ligature sutures dissolved (approximately 5-6 weeks). Thereafter, topical aqueous suppressant was titrated to aim for IOP in the low teens.

Control of IOP was the primary outcome measurement. Complete (IOP control without antiglaucoma medications) and qualified successes (IOP control with antiglaucoma medications) were calculated based on standard definitions used previously.⁵ In summary, cumulative failure rate of the AADI was defined as IOP >18 mm Hg or not reduced by at least 30% below baseline on 2 consecutive follow-up visits after 3 months, IOP ≤5 mm Hg on 2 consecutive follow-up visits after 3 months, reoperation for glaucoma or a⁵ complication, or loss of light perception vision.

- **STATISTICAL ANALYSIS:** All continuous variables were described as means with standard deviations or medians with interquartile range (IQR), and categorical variables were described as proportions (n, %). Visual acuity was converted to logarithm of minimum angle of resolution (logMAR) for statistical analysis. Groupwise comparisons in the groups with and without scleral patch graft were made using the Student *t*-test or Wilcoxon rank-sum test for continuous variables. The chi-square test or Fisher exact test was used to analyze group differences across categorical variables. Comparison of IOP values between pre and post-

TABLE 1. Baseline Demographics and Clinical Characteristics of Adult and Pediatric Eyes with and without Scleral Patch Graft

Variables	No Patch Graft (n = 68)	Patch Graft (n = 147)	P Value
Adult Glaucoma			
Mean ± SD age, y	46.4 ± 16.8	44.5 ± 17.3	.45
Males	22 (32%)	37 (25%)	.27
Mean ± SD MD, dB	-14.7 ± 8.6	-17.5 ± 9.3	.74
Mean ± SD PSD, dB	9.5 ± 2.7	10.2 ± 3.6	.88
Lens status: phakic	26 (38%)	69 (47%)	.42
Aphakic	11 (16%)	24 (16%)	
Pseudophakic	31 (46%)	54 (37%)	
Type of glaucoma			.31
POAG	14 (20%)	35 (24%)	
PACG	3 (4%)	12 (8%)	
SOAG	19 (28%)	29 (20%)	
SACG	23 (34%)	46 (31%)	
JOAG	5 (7%)	12 (8%)	
Congenital/developmental	4 (6%)	13 (8%)	
Prior trabeculectomy	37 (54%)	94 (64%)	.86
Monocular status	5 (7%)	20 (13%)	.25
Pediatric glaucoma			
Number of eyes	n = 38	n = 73	
Mean ± SD age, y	9.8 ± 4.7	10.3 ± 4.7	.64
Boys	20 (53%)	44 (60%)	
Type of glaucoma			
Primary congenital glaucoma	12 (32%)	21 (29%)	.82
Glaucoma after cataract surgery	10 (26%)	25 (34%)	
Glaucoma associated with congenital eye and systemic anomalies	5 (13%)	5 (7%)	
Glaucoma associated with congenital eye anomalies alone	3 (8%)	6 (8%)	
Glaucoma with acquired conditions	7 (18%)	12 (16%)	
Juvenile open angle glaucoma	1 (3%)	4 (6%)	
Prior filtration surgery	18 (47%)	41 (56%)	.62
Repeat trabeculectomy	2 (5%)	8 (11%)	.23

dB = decibel; JOAG = juvenile open angle glaucoma; MD = mean deviation; PACG = primary angle closure glaucoma; POAG = primary open angle glaucoma; PSD = pattern standard deviation; SACG = secondary angle closure glaucoma; SD = standard deviation; SOAG = secondary open angle glaucoma.

AADI at different time intervals were carried out using one-way ANOVA with Bonferroni adjustments. Data from adult and pediatric eyes were presented separately, and no comparisons were made between these disparate groups.

Survival analysis was performed and Kaplan-Meier curves were plotted to depict cumulative survival rates at various time points. Differences between cumulative survival curves were determined using the log-rank test. The survival probability for each outcome was assessed using the Cox proportional hazards models and displayed using hazard ratios (HR) with 95% confidence intervals (CI). Covariates used for adjusting HRs were those with a *P* value of <.1 in univariate models and those that have been shown to influence failure rates in previous studies.

Data were entered into an Excel spreadsheet (Microsoft, Redmond, Washington) and analyzed using STATA

version 12.1 software (StataCorp, Fort Worth, Texas), and a *P* value <.05 was considered statistically significant.

RESULTS

A TOTAL OF 215 EYES OF 215 ADULTS WERE INCLUDED (N = 147 with patch grafts, and n = 68 without patch grafts) and 111 eyes of 111 children (n = 73 with patch grafts, and n = 38 without patch grafts) that satisfied the inclusion criteria during the study period. The demographics and baseline characteristics of enrolled patients are shown in Table 1. There were no significant differences between eyes that received the scleral patch graft and those that did not. In adult eyes, there were more secondary glaucomas than primary glaucomas, with neovascular glaucoma (n = 21

TABLE 2. Intraocular Pressure, Antiglaucoma Medications, and Visual Acuity at Baseline and Follow-Up in Adult and Pediatric Eyes with and without Scleral Patch Graft

Variables	Adult Eyes ^a			Pediatric Eyes ^a		
	No Patch Graft (n = 68)	Patch Graft (n = 147)	P Value	No Patch Graft (n = 38)	Patch Graft (n = 73)	P Value
Baseline						
IOP	33.4 (11.2)	34.7 (9.9)	.33	33.7 (9.7)	34.2 (9.4)	.78
Anti-glaucoma medications	3.2 (0.9)	3.2 (0.7)	.60	2.8 (0.7)	2.8 (0.7)	.88
LogMAR VA	0.62 (0.69)	0.52 (0.48)	.79	0.83 (0.58)	0.73 (0.52)	.39
1 month						
IOP	27.5 (14.1)	22.3 (11.1)	.01	14.3 (5.8)	17.8 (11.0)	.39
Anti-glaucoma medications	2.3 (0.9)	2.0 (0.9)	.13	1.7 (0.7)	1.4 (0.9)	.12
LogMAR VA	0.72 (0.77)	0.71 (0.57)	.40	0.89 (0.37)	0.77 (0.11)	.44
3 mo						
IOP	16.8 (8.3)	17.4 (8.7)	.81	14.3 (8.1)	16.2 (7.6)	.18
Anti-glaucoma medications	1.6 (1.0)	1.5 (1.0)	.36	1.4 (0.8)	1.3 (0.9)	.53
LogMAR VA	0.79 (0.77)	0.67 (0.61)	.71	0.91 (0.69)	0.81 (0.62)	.57
6 mo						
IOP	15.3 (7.7)	15.3 (6.0)	.57	14.1 (8.4)	14.2 (6.8)	.35
Anti-glaucoma medications	1.4 (1.0)	1.5 (1.0)	.53	0.9 (0.9)	1.2 (0.9)	.10
LogMAR VA	0.78 (0.85)	0.70 (0.63)	.62	0.88 (0.73)	0.93 (0.70)	.61
12 mo						
IOP	16.3 (9.5)	14.6 (4.5)	.87	15.5 (8.1)	14.7 (6.7)	.89
Anti-glaucoma medications	1.5 (1.0)	1.5 (1.0)	.92	1.0 (1.0)	1.1 (1.0)	.52
LogMAR VA	0.90 (0.91)	0.66 (0.61)	.22	0.88 (0.81)	0.97 (0.77)	.71
18 mo						
IOP	15.3 (8.8)	15.2 (6.3)	.26	15.3 (7.6)	14.9 (5.2)	.61
Anti-glaucoma medications	1.3 (0.9)	1.4 (1.0)	.64	1.4 (1.0)	1.1 (1.0)	.26
LogMAR VA	0.91 (0.95)	0.74 (0.72)	.61	0.95 (0.88)	1.0 (0.83)	.62
24 mo						
IOP	14.4 (6.5)	15.4 (6.3)	.44	15.0 (6.9)	15.8 (7.1)	.74
Anti-glaucoma medications	1.5 (1.0)	1.5 (1.0)	.82	1.0 (0.9)	1.1 (1.1)	.70
LogMAR VA	0.86 (0.91)	0.77 (0.78)	.75	0.84 (0.81)	1.1 (0.84)	.09

IOP = intraocular pressure; LogMAR VA = logarithm of the minimum angle of resolution visual acuity.

^aData are presented as mean ± SD.

[10%]), pseudoexfoliation glaucoma (n = 13 [6%]), silicone oil-induced glaucoma (n = 14 [6.5%]), aphakic glaucoma (n = 15 [7%]) and uveitic glaucoma (n = 17 [8%]) were the most common. Overall, 61% of adult eyes had undergone trabeculectomy, whereas the rest were treatment naïve. In children, primary congenital glaucoma (n = 33 [30%]) and glaucoma following cataract surgery (n = 35 [32%]) were the most common forms of glaucoma.

The IOP, number of antiglaucoma medications, BCVA at baseline, and each time point during the follow-up are shown in Table 2. There was a significant reduction in mean IOP at 1 month follow-up in both adult ($P < .001$) and pediatric eyes ($P < .001$). The mean IOP stabilized after the 1-month follow-up. Distribution of median IOP at each time point is shown in Figure 1. The mean IOP in eyes without the patch graft was higher at 1 month in adult eyes, but there were no differences in IOP between groups at all other time points. The mean number of antiglaucoma medications also were reduced significantly (Table 2) at the 1-month time point

($P < .001$) in both adult and pediatric eyes. The mean follow-up was significantly greater in the patch group than in the patch-free group in both adult (48.4 ± 16.2 vs 27.3 ± 1.9 months, respectively; $P < .001$) and pediatric eyes (46.3 ± 14.5 vs $24.3 \pm .61$ months, respectively; $P < .001$).

There were no differences in the rates of complications between eyes that underwent AADI with the scleral patch graft and those that did not receive the patch graft (Table 3). There were no tube exposures in the no-patch group in either the adult and the pediatric eyes, whereas this was seen in less than 2% of adult eyes (n = 2) and less than 10% in pediatric eyes (n = 7) in the patch graft group. These differences were not statistically significant. The 2 eyes in the adult cohort manifested this in the first and sixth postoperative months (Figure 2A), whereas 5 of 7 pediatric eyes showed exposure (Figure 2B) at 7.2 ± 1.5 months postoperatively, and 1 eye showed endothelial touch and high IOP and eventually tube exposure at 40 months, and the other resulted in tube exposure post-

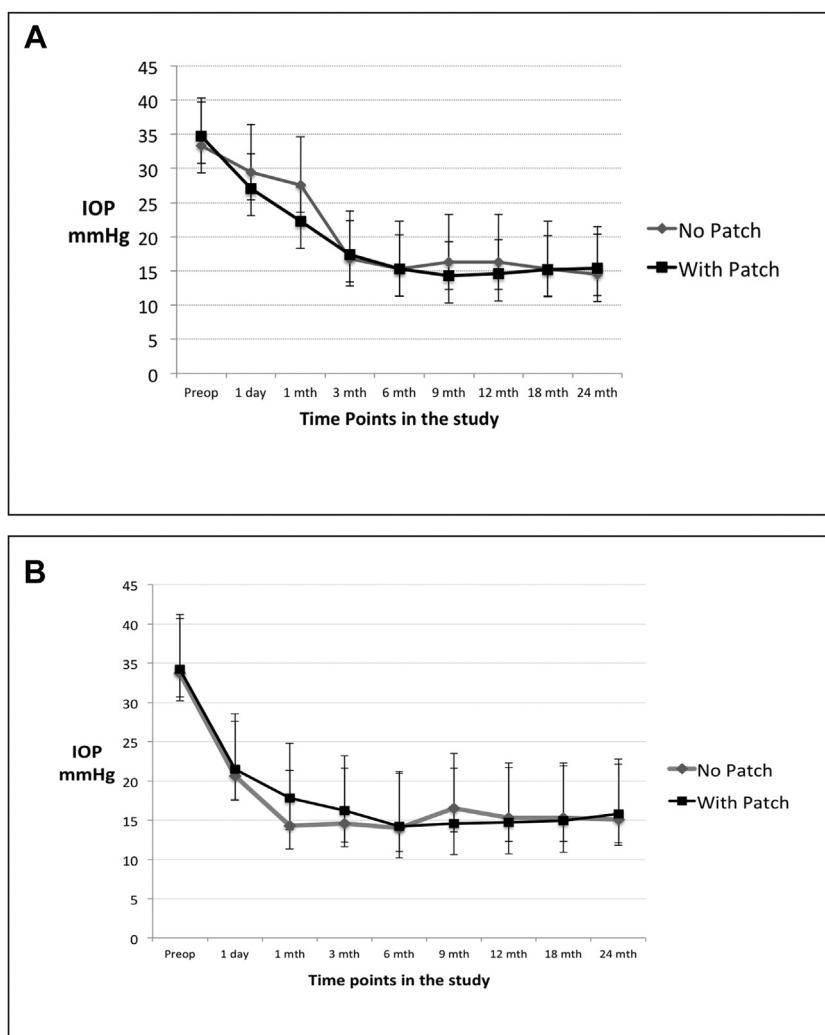


FIGURE 1. Distribution of mean IOP in adult (A) and pediatric (B) groups during the follow-up time points.

patch graft melt at 56 months. Transient choroidal detachment was the most common in both groups in the adult eyes, whereas corneal endothelial touch was the most common complication in pediatric eyes (Table 3). Cataract surgery was the most common reoperation in both groups of adult eyes, and tube trimming was the most common resurgery in pediatric eyes with patch graft and in those without, tube trimming, and tube repositioning were the most common surgeries (Table 4). There were no significant differences between rates of reoperation in eyes with and those without the scleral patch graft (Table 4).

A comparison of success rates, both absolute and cumulative, between eyes with and without the scleral patch graft is shown in Table 5. Of the 76 adult eyes which failed at 2 years, 21 (27%) were due to a complication or reoperation, 2 (3%) were due to persistent hypotony, and the remaining 53 (70%) were due to uncontrolled IOP. Cumulative failure rates at different time points in adult and pediatric eyes are shown in Figure 3. In pediatric eyes, of 28 failures, 23 (82%) were due to uncontrolled IOP, 1 was due to persistent hypot-

ony, and 4 (14%) were due to complications. There were no differences in the cumulative complete and qualified success rates in eyes with and without the patch graft (Table 5), in adult as well as in pediatric eyes. Cox proportional hazards models, after adjusting for age, sex, primary versus secondary glaucoma, and open versus closed angle glaucomas did not reveal any factor that was associated with significantly higher rates of failure, either in the pediatric or in adult eyes. Post hoc analysis showed that the study had a 62% and 56% power for determining differences in complete success between groups, whereas it was underpowered (13% and 26%, respectively) to determine differences in complications between groups in adult and pediatric eyes.

DISCUSSION

THIS COMPARATIVE STUDY FOUND THAT EYES THAT UNDERWENT AADI IMPLANTATION USING A NEEDLE-GENERATED

TABLE 3. Complications in Adult and Pediatric Eyes with and without Scleral Patch Graft Up To 2 Years Follow-Up

Complications	Adult Eyes			Pediatric Eyes		
	No Patch Graft (n = 68)	Patch Graft (n = 147)	P Value	No Patch Graft (n = 38)	Patch Graft (n = 73)	P Value
Tube-related complications			.37			.40
Tube exposure	0	2 (1.4%)		0	5 (7%)	
Plate exposure	0	0		0	0	
Tube retraction	0	0		2 (5%)	1 (1%)	
Tube occlusion (by iris/vitreous)	3 (4.4%)	1 (0.6%)		1 (3%)	4 (5%)	
Plate migration	0	1 (0.6%)		1 (3%)	3 (4%)	
Other complications			.12			.40
Choroidal detachment	7 (10.2%)	9 (6%)		2 (5%)	4 (5%)	
Endothelial touch	0	0		3 (8%)	5 (7%)	
Retinal detachment	1 (1.4%)	0		0	2 (3%)	
Corneal decompensation	2 (3%)	3 (2.04%)				
Macular edema	0	5 (3.4%)		0	1 (1%)	
Tube occlusion (by fibrin)	1 (1.4%)	4 (2.7%)				
Severe anterior uveitis	3 (4.4%)	1 (0.6%)		0	2 (3%)	
Hypotony	0	2 (1.4%)		1 (3%)	1 (1%)	
Vitreous hemorrhage	0	0		1 (3%)	1 (1%)	
Endophthalmitis	0	0		0	2 (3%)	
Orbital cellulitis	0	0		0	1 (1%)	
Total number of patients with complications	17 (25%)	28 (19%)	.42	11 (29%)	32 (44%)	.32

Data are n (%) of eyes in each cohort.

scleral tunnel without a scleral patch graft experienced IOP reduction that was equivalent to and had complication and reoperation rates similar to the eyes that received the AADI with a scleral patch graft. Importantly, none of the eyes in the no-patch group experienced tube exposure over the 2 years follow-up, whereas this was infrequently observed in eyes that received the patch graft. The cumulative success rates in both adult and pediatric eyes were similar to the rates previously published with the AADI implant.

Glaucoma drainage implants have gained popularity in the management of refractory glaucoma,¹ sometimes as the first option in surgery naïve eyes such as those with secondary glaucomas, due to their impressive IOP-lowering effects, albeit at a slightly greater risk of complications than trabeculectomy.¹⁷ Conventionally, the tubes of the drainage implants are secured to the sclera near the limbus and covered with a scleral patch graft to prevent tube exposure and its resultant complications. The need for a donor scleral patch graft limits the use of these implants in view of lack of reliable eye banking facilities in much of the developing world. Additionally, it also poses concerns about transmission of pathogens such as prions from donor tissue and increases the cost of surgery.¹⁸ To overcome these barriers, graft-free implantation techniques have been described previously while using the Ahmed valve as well as the Baerveldt and Molteno implants with varying degrees of success.^{8-11,13,19}

In a study of refractory pediatric glaucomas published 10 years ago, Oscar and associates⁸ described a technique similar to the present one in which a needle-generated scleral track was created 3-4 mm from the limbus, and the Ahmed valve tube was inserted into the anterior chamber. Authors studied 106 eyes of Mexican children and found cumulative success rates of approximately 70% at 2 years, similar to the present results. The authors did not report any tube exposure or extrusions in this series of pediatric eyes, similar to the present experience. The differences in surgical technique were that, in the present study, intraoperatively, the tube was marked prior to trimming and the initial scleral groove for the site of initiation of the scleral track was also marked thereby attaining an optimum 2- to 2.5-mm length of the tube in the anterior chamber and 4mm sclera track. Both for right and left eyes, the needle-generated scleral track is medial so that the tube enters the eye at approximately around 12 O'clock position, probably thereby reducing the risk of tube exposures, tubes at 12 O'clock have the least contact with the eyelid. The initial sinuous route of implantation has the potential advantage of the adequate length of the tube being still available in case secondary interventions need to be done in situations like tube retraction, tube exposure and tube cornea touch.

In a recent randomized controlled trial comparisons, Pakravan and associates¹² compared the safety and efficacy of graft-free short tunnel small flap technique (n =

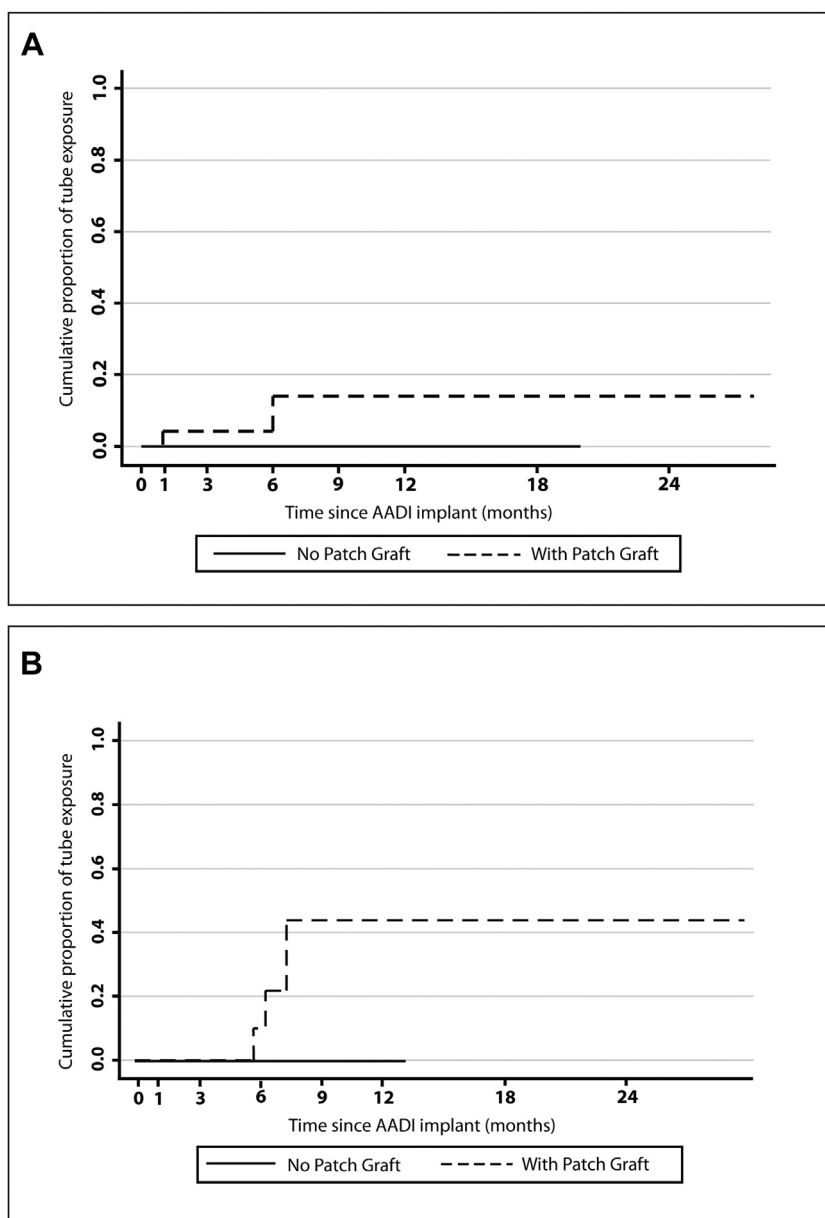


FIGURE 2. Kaplan-Meier survival curves showing time points of tube exposure in adult (A) and pediatric (B) eyes.

102) with that of the scleral patch graft (n = 101) in Ahmed glaucoma valve implantation. At the end of 1 year, only one patient (1%) in the graft-free group developed tube exposure, and the cumulative success rate in this group was 70%, similar to the present results. Pakravan and associates,²⁰ in a previous noncomparative study, albeit with a smaller sample size (n = 16), showed similar success with no tube exposure or conjunctiva-related complication in eyes receiving the Ahmed valve at 1 year follow-up. Ma and associates¹¹ have described a modified scleral tunnel technique to implant the Ahmed tube similar to that described in the present study and showed no tube exposure in all 36 eyes followed for 1

year. Gdih and associates⁹ described a longer scleral tunnel of approximately 6 mm to implant the Ahmed valve in 83 eyes and reported no scleral erosions over 2 years. Authors also reported a 39%-45% reduction in the cost of surgery compared to that with a patch graft. Rossiter-Thornton¹⁹ showed good outcomes at 10 years after implanting the Molteno tube without a patch graft. Other innovative techniques such as the double-scleral tunnel in tandem¹³ and long scleral flap augmented with tenon advancement and duplication have also been described in the past.¹⁴ To the best of the present authors' knowledge, this is the first study showing the efficacy and safety of the AADI implanted without a scleral patch graft in

TABLE 4. Reoperations in Adult and Pediatric Eyes with and without Scleral Patch Graft up to 2 Years Follow-Up

Reoperations	Adult Eyes			Pediatric Eyes		
	No Patch Graft (n = 68)	Patch Graft (n = 147)	P Value	No Patch Graft (n = 38)	Patch Graft (n = 73)	P Value
Tube ligation	0	1 (0.6%)	.28	1 (3%)	2 (3%)	.06
Tube trimming	0	1 (0.6%)		2 (5%)	6 (8%)	
Tube repositioning	0	0		2 (5%)	3 (4%)	
PPV ±SOI	3 (4.4%)	3 (2%)		0	4 (5%)	
Choroidal drainage	1 (1.4%)	2 (1.4%)		1 (3%)	0	
Repeat AADI	0	1 (0.6%)		1 (3%)	3 (4%)	
AADI exchange	0	1 (0.6%)		0	0	
AADI explantation	1 (1.4%)	2 (1.4%)		0	0	
Iris repositioning	0	1 (0.6%)		0	0	
Cataract surgery	5 (7.3%)	13 (8.8%)		0	3 (4%)	
PK	0	0		0	1 (1.3%)	
Repeat PK	0	3 (2%)		0	0	
Cyclophotocoagulation	4 (6%)	1 (0.6%)		1 (3%)	0	
Total number of reoperations	14 (20.5%)	29 (20%)	.86	8 (10%)	22 (30%)	.28

AADI = Aurolab Aqueous Drainage Implant; PK = penetrating keratoplasty; PPV = pars plana vitrectomy; SOI = silicone oil infusion.
Data n (%) of eyes in each cohort.

TABLE 5. Comparison of Success at Various Time Points in Adult and Pediatric Eyes with and without Scleral Patch Graft

Success At Time Point	Adult Glaucomas			Pediatric Glaucomas		
	No Patch Graft (n = 68)	Patch Graft (n = 147)	P Value	No Patch Graft (n = 38)	Patch Graft (n = 73)	P Value
Complete success (absolute) ^a	36 (53%)	72 (49%)	.58	25 (66%)	38 (52%)	.16
Qualified success (absolute) ^a	45 (66%)	94 (64%)	.75	30 (79%)	53 (73%)	.46
Cumulative success at each time point (complete success)						
6 mo	89.7% (79.6-94.5%)	91.2% (85.3-94.7%)	.76	92.1% (77.4-97.3%)	87.6% (77.6-93.4%)	.39
12 mo	73.5% (61.3-82.4%)	76.8% (69.2-82.8%)		78.9% (62.3-88.8%)	72.6% (60.8-81.3%)	
18 mo	61.7% (49.2-72.1%)	63.9% (55.6-71.1%)		67.6% (50.1-80.2%)	67.1% (55.1-76.6%)	
24 mo	52.9% (40.7-63.9%)	48.9% (40.6-63.9%)		63.6% (45.3-77.3%)	51.4% (39.3-62.2%)	
Cumulative success at each time point (qualified success)						
6 mo	94.1% (85-97%)	94.5% (89.7-97.2%)	.85	94.7% (80.6-98.6%)	97.2% (89.5-99.3%)	.83
12 mo	83.8% (72.7-90.7%)	89.1% (82.8-93.2%)		84.2% (68.2-92.5%)	84.9% (74.4-91.3%)	
18 mo	79.4% (67.7-87.2%)	80.3% (72.8-85.5%)		81.3% (64.7-90.6%)	84.9% (74.4-91.3%)	
24 mo	66.2% (53.6-76.1%)	63.9% (55.6-71.1%)		77.2% (59.1-88.1%)	71.9% (59.9-80.4%)	

Cumulative complete and qualified success expressed as a percentage (95% confidence interval).

^aComplete and qualified success values calculated at 2 year time point expressed in numbers (percentage).

adult and pediatric eyes at 2 years' time point. The fact that none of the eyes in this group showed scleral thinning and de-roofing leading to tube exposure is encouraging for patch-free tube implantation.

The results of the group with the patch graft are similar to previous studies reported using the AADI in both adult and pediatric eyes. A randomized controlled study in adult

refractory glaucoma comparing the AADI to the Ahmed glaucoma valve by Rathi and associates²¹ showed that the complete success rate was higher in the AADI group (68.42%) than in the AGV group (26.31%) at 6 months' follow-up. In another comparative study, Pandav and associates²² concluded that both AADI and Ahmed implants had comparable mean IOP at 3 years with lesser

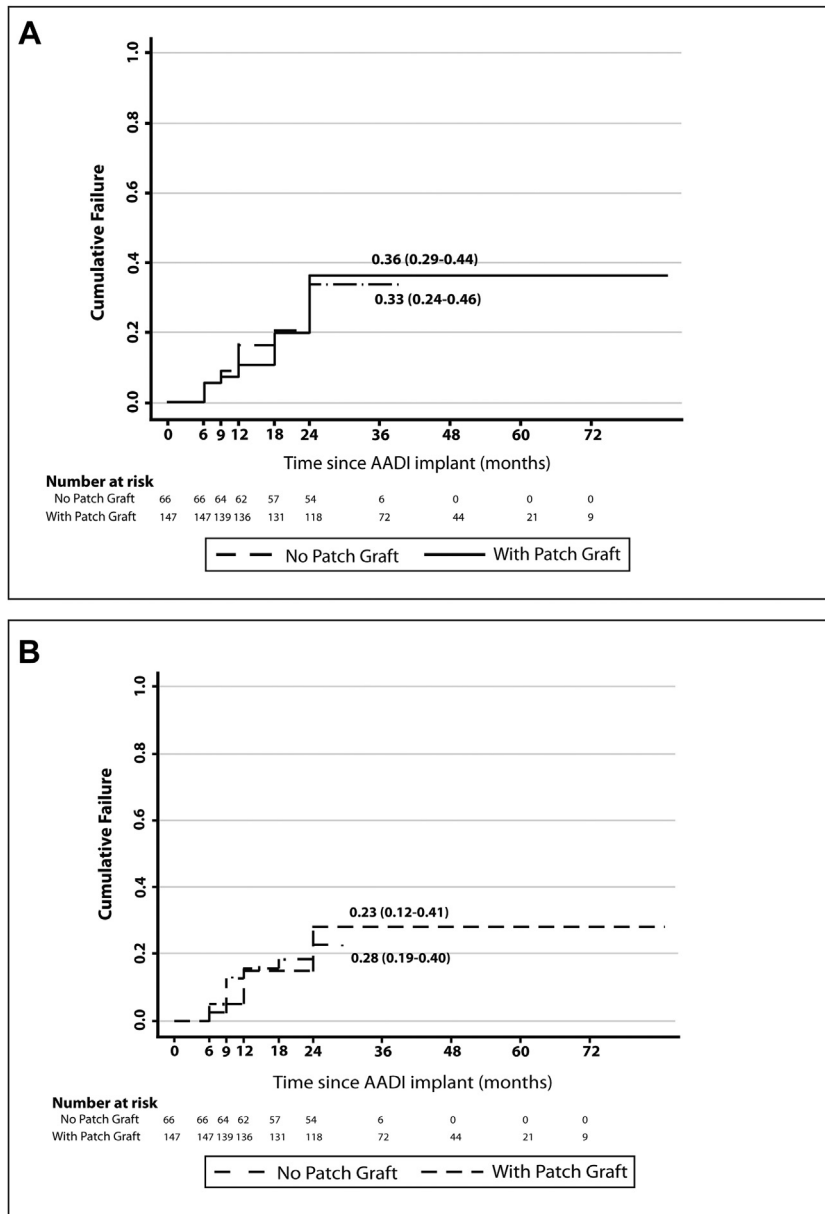


FIGURE 3. Kaplan-Meier survival curves showing cumulative rates of qualified success in adult (A) and pediatric (B) eyes.

requirement of antiglaucoma medications in the AADI group.²² Kaushik and associates²³ have also shown good results in pediatric eyes using the AADI implant in the past.

Tube exposures were greater in the pediatric (9%) than in the adult (1.4%) patients in the patch graft group. This trend of higher tube exposure in children is seen in almost all previous studies of this subject.²⁴⁻²⁶ This may be related to the difference in the inflammatory and wound healing responses mounted in pediatric eyes, which differ from those in adult eyes, although this is still a postulation. The greater elasticity of children's sclera allows movement of the tube within the tissue, or their tendency to rub their eyes, are also possible reasons.

Tube exposure is of paramount concern when implanting the tube without a scleral patch graft. This technique is much less studied than that of the patch graft precisely for this reason. However, almost all the studies using modified scleral tunnels and flaps do not report an incidence of tube exposure of more than 2%-3% in eyes without the patch graft. Tube exposure possibly results from continuous friction between the tube material and the overlying tissue leading to persistent inflammation and conjunctival and scleral necrosis. These authors hypothesize that a donor patch graft, due to its elevated nature, makes the ocular surface more uneven and prone to localized tear film disturbances, precipitating increased inflammation and

conjunctival and scleral necrosis.⁷ The graft-free technique, by virtue of having the tube embedded within the patients' own sclera, leads to less elevation and a smoother ocular surface, thereby leading to lesser inflammation and better wound healing. A caveat is to have a scleral tunnel of sufficient depth and length so that the tube is buried well inside the scleral tissue. Passing the flexible tube through the narrow scleral tunnel can be challenging in the beginning but is amenable to making a second needle pass if needed as the long needle track is usually self-sealing. Additionally, getting the path right can be aided by using an upward lift on the syringe holding the needle during the pass, as this aids in obtaining a downward "U" path through the tissue. Conversely, if one inadvertently leans the weight of the hand on the needle or creates a path that appears straight while the stiff needle is in place but has an upward path near the entry point when the flexible tube is inserted, it leads to the tube being closer to the cornea than expected, with associated complications. Furthermore, and quite importantly, a longer needle track helps prevent late migration of the tube tip toward the cornea by virtue of distributing resistance to straightening of the tube over a greater path, whereas a short path through sclera near the limbus presents a less adequate resistance to the straightening force ("memory") of the silicone tube. Last, it is imperative to cover the buried tube under Tenon's fascia with a good conjunctival cover to minimize the risk of tube exposure.

The drawbacks of the study are its retrospective nature and time-bound inclusion of cases before and after December 2015, leading to differences in total follow-up. Additionally, due to the small number of tube exposures overall, the study was underpowered to find significant differences in tube exposure between groups. Also, surgery by

2 surgeons may have influenced the results. The strengths of this study are the presence of a comparison group and the relatively large number of eyes with a minimum of 2 years' follow-up.

In conclusion, the implantation of the AADI tube through a needle-generated scleral tunnel without a donor scleral patch graft was as safe and effective as the conventional technique of implantation using the patch graft. Longer-term prospective comparative studies with the AADI and with tube exposure as the primary outcome are required to assess tube related complication when implanted without the patch graft. However, the very low incidence of tube exposure seen in medical literature, corroborated by the present findings, suggest that surgeons can adopt this technique going forward, leading ultimately to more widespread adoption of glaucoma drainage devices at potentially lower costs.

CRediT AUTHORSHIP CONTRIBUTION STATEMENT

GEORGE VARGHESE PUTHURAN: CONCEPTUALIZATION, Formal analysis, Methodology, Writing - review & editing. **Paul Palmberg:** Conceptualization, Formal analysis, Methodology, Writing - review & editing. **Hiruni Kaushalya Wijesinghe:** Data curation, Formal analysis, Writing - original draft, Writing - review & editing. **Kumar Saurabh Srivastav:** Data curation, Writing - original draft. **Subbaiah Ramasamy Krishnadas:** Conceptualization, Methodology, Writing - review & editing. **Alan Lee Robin:** Conceptualization, Methodology, Writing - review & editing.

ALL AUTHORS HAVE COMPLETED AND SUBMITTED THE ICMJE FORM FOR DISCLOSURE OF POTENTIAL CONFLICTS OF INTEREST and none were reported.

Funding/Support: No outside funding was received for this work.

Financial Disclosures: P.P. is a consultant for and has received honoraria and travel support from InnFocus, Inc, a Santen company, for the US Food and Drug Administration MicroShunt trial; and has received honoraria and travel support as an invited speaker at Moorfields Eye Hospital, the Moroccan Ophthalmology Society, the Kuwaiti Ophthalmology Society, and Doheny Eye Institute UCLA. A.L.R. is a consultant for Versant Eye Institute and Perfuse Therapeutics. All other authors have reported that they have no relationships relevant to the contents of this paper to disclose.

The authors acknowledge the inputs from Dr Sabyasachi Sengupta for statistical analysis.

REFERENCES

1. Arora KS, Robin AL, Corcoran KJ, Corcoran SL, Ramulu PY. Use of various glaucoma surgeries and procedures in Medicare beneficiaries from 1994 to 2012. *Ophthalmology* 2015;122:1615–1624.
2. Christakis PG, Zhang D, Budenz DL, Barton K, Tsai JC, Ahmed IIK, for the ABC-AVB Study Groups. Five-year pooled data analysis of the ahmed baerveldt comparison study and the Ahmed versus Baerveldt study. *Am J Ophthalmol* 2017;176:118–126.
- 3.. Palmberg P, Puthuran GV, Wijesinghe HK, Krishnadas SR, Robin A. Intermediate -Term outcomes of an affordable aqueous drainage implant in adults with refractory glaucoma. *Ophthalmol Glaucoma* 2019;2:258–266.
4. Philip R, Chandran P, Aboobacker N, Dhavalikar M, Raman GV. Intermediate-term outcome of Aurolab aqueous drainage implant. *Indian J Ophthalmol* 2019;67:233.
5. Puthuran GV, Palmberg PF, Wijesinghe HK, Pallamparthi S, Krishnadas SR, Robin AL. Intermediate-term outcomes of Aurolab aqueous drainage implant in refractory pediatric glaucoma. *Br J Ophthalmol* 2019. Available at: <https://bjoo>.

- bmj.com/content/early/2019/10/03/bjophthalmol-2019-314399. Accessed April 22, 2020.
6. Wishart PK, Choudhary A, Wong D. Ahmed glaucoma valves in refractory glaucoma: a 7-year audit. *Br J Ophthalmol* 2010;94:1174–1179.
 7. Chaku M, Netland PA, Ishida K, Rhee DJ. Risk factors for tube exposure as a late complication of glaucoma drainage implant surgery. *Clin Ophthalmol* 2016;10:547–553.
 8. Albis-Donado O, Gil-Carrasco F, Romero-Quijada R, Thomas R. Evaluation of Ahmed glaucoma valve implantation through a needle-generated scleral tunnel in Mexican children with glaucoma. *Indian J Ophthalmol* 2010;58:365–373.
 9. Gdih G, Jiang K. Graft-free Ahmed valve implantation through a 6 mm scleral tunnel. *Can J Ophthalmol* 2017;52:85–91.
 10. Gedar Totuk OM, Kabadayi K, Colakoglu A, Ekizoglu N, Aykan U. A novel surgical technique for prevention of Ahmed glaucoma valve tube exposure: long scleral flap augmented with Tenon advancement and duplication. *BMC Ophthalmol* 2018;18:226.
 11. Ma X-H, Du X-J, Liu B, Bi H-S. Modified scleral tunnel to prevent tube exposure in patients with refractory glaucoma. *J Glaucoma* 2016;25:883–885.
 12. Pakravan M, Hatami M, Esfandiari H, et al. Ahmed glaucoma valve implantation: graft-free short tunnel small flap versus scleral patch graft after 1-year follow-up: a randomized clinical trial. *Ophthalmol Glaucoma* 2018;1:206–212.
 13. Brouzas D, Dettoraki M, Andreanos K, Nomikarios N, Koutsandrea C, Moschos MM. “Double scleral tunnel in tandem” technique for glaucoma drainage tube implants. *Int Ophthalmol* 2018;38:2349–2356.
 14. Tamcelik N, Ozkok A, Sarıcı AM, Atalay E, Yetik H, Gungor K. Tenon advancement and duplication technique to prevent postoperative Ahmed valve tube exposure in patients with refractory glaucoma. *Jpn J Ophthalmol* 2013;57:359–364.
 15. Gutiérrez-Díaz E, Montero-Rodríguez M, Mencía-Gutiérrez E, Cabello A, Monescillo J. Long-term persistence of fascia lata patch graft in glaucoma drainage device surgery. *Eur J Ophthalmol* 2005;15:412–414.
 16. Lind JT, Shute TS, Sheybani A. Patch graft materials for glaucoma tube implants. *Curr Opin Ophthalmol* 2017;28:194–198.
 17. Gedde SJ, Schiffman JC, Feuer WJ, Herndon LW, Brandt JD, Budenz DL, for the Tube versus Trabeculectomy Study Group. Treatment outcomes in the Tube Versus Trabeculectomy (TVT) study after five years of follow-up. *Am J Ophthalmol* 2012;153:789–803.
 18. Mehta JS, Franks WA. The sclera, the prion, and the ophthalmologist. *Br J Ophthalmol* 2002;86:587–592.
 19. Rossiter-Thornton L, Azar D, Leong J, Lightman S, Towler HMA, McCluskey P. Graft-free Molteno tube insertion: 10-year outcomes. *Br J Ophthalmol* 2010;94:665–666.
 20. Pakravan M, Hekmat VR, Pakravan P, Hassanpour K, Esfandiari H. Graft-free glaucoma drainage device implantation: short tunnel small flap technique. *Eur J Ophthalmol* 2019;29:57–60.
 21. Rathi SG, Seth NG, Kaur S, et al. A prospective randomized controlled study of Aurolab aqueous drainage implant versus Ahmed glaucoma valve in refractory glaucoma: a pilot study. *Indian J Ophthalmol* 2018;66:1580–1585.
 22. Pandav SS, Seth NG, Thattarathody F, et al. Long-term outcome of low-cost glaucoma drainage device (Aurolab aqueous drainage implant) compared with Ahmed glaucoma valve. *Br J Ophthalmol* 2019. Available at: <https://bjo.bmj.com/content/early/2019/07/03/bjophthalmol-2019-313942>. Accessed April 22, 2020.
 23. Kaushik S, Kataria P, Raj S, Pandav SS, Ram J. Safety and efficacy of a low-cost glaucoma drainage device for refractory childhood glaucoma. *Br J Ophthalmol* 2017;101:1623–1627.
 24. Mandalos A, Sung V. Glaucoma drainage device surgery in children and adults: a comparative study of outcomes and complications. *Graefes Arch Clin Exp Ophthalmol* 2017;255:1003–1011.
 25. Chen A, Yu F, Law SK, Giaconi JA, Coleman AL, Caprioli J. Valved glaucoma drainage devices in pediatric glaucoma: retrospective long-term outcomes. *JAMA Ophthalmol* 2015;133:1030–1035.
 26. Senthil S, Gollakota S, Ali MH, et al. Comparison of the new low-cost nonvalved glaucoma drainage device with Ahmed glaucoma valve in refractory pediatric glaucoma in Indian eyes. *Ophthalmol Glaucoma* 2018;1:167–174.